

March 2000

Vol. 25

No. 3

U.S. \$4

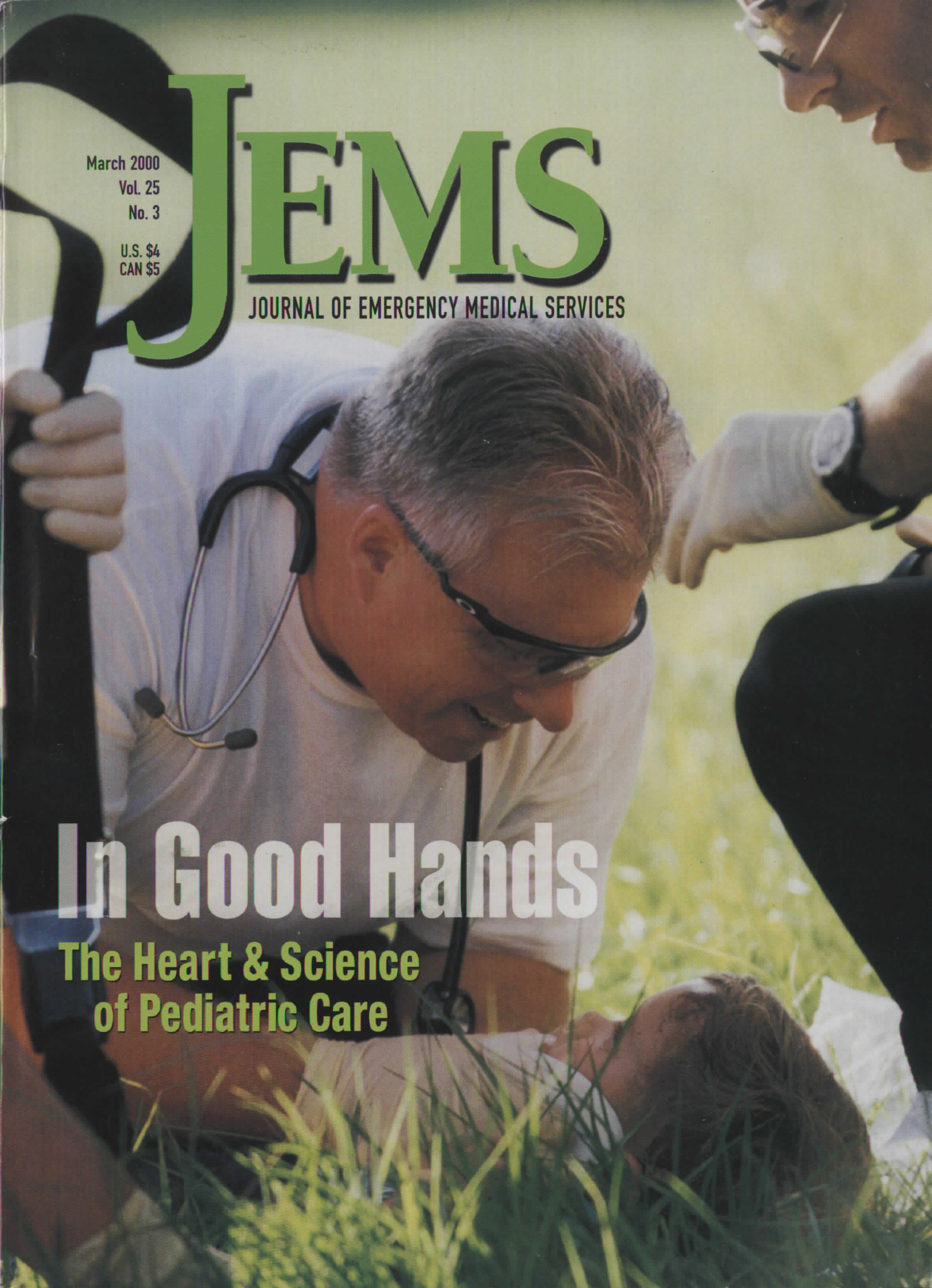
CAN \$5

JEMIS

JOURNAL OF EMERGENCY MEDICAL SERVICES

In Good Hands

The Heart & Science
of Pediatric Care



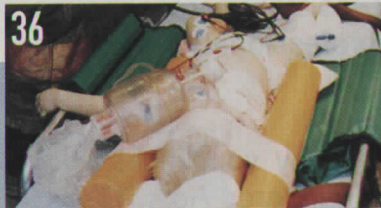

C O N T E N T S

Features

36 **SPECIAL SECTION**

JEMS' annual guide to pediatric care



36

38 **20 Things You May Not Know about Pediatrics**

By Ronald M. Perkin, MD, MA & Daved van Stralen, MD

50 **Pediatric Passages**

10 pitfalls to avoid in pediatric airway management

By Ronald M. Perkin, MD, MA & Daved van Stralen, MD

66 **Little Lifelines**

Smart strategies for establishing peripheral vascular access in pediatrics.

By Connie J. Mattera, MS, RN

82 **Special Kids, Special Care**

Emergency management of children with special health-care needs

By Elizabeth Smith, RN, NREMT-P, Terry A. Adirim, MD, MPH, & Tasmeen Singh, NREMT-P

94 **Service Revolution**

Pridemark Paramedic Services takes service to a new level

By Mike Taigman

104 **The Tree of Life**

Remembering those who died in the line of duty.

By Sandra Fry, RN, EMT-P


108 **EMS Workforce**

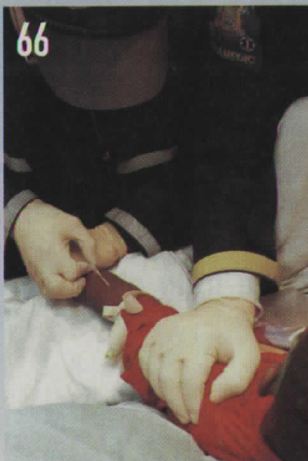Changes in the nation's EMS workforce.

By A.J. Heightman

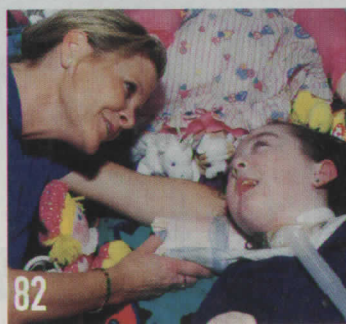114 **Hepatitis C**

By Chris Coughlin, BA, NREMT-P & Alissa Craft, DO

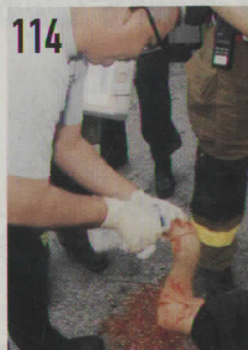
 CE Article



66



82



114

Columns

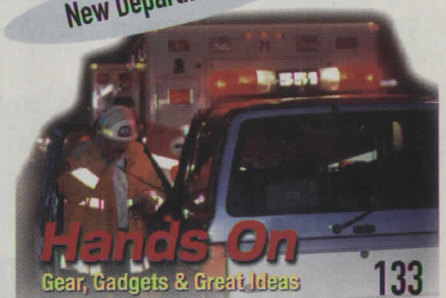
9 **From the Editor**
Staying on the Pulse of EMS
By A.J. Heightman

28 **Case of the Month**
Memory Lapse
By Paul A. Werfel

140 **Street Law**
Sign Here & We're Gone
By Douglas M. Wolfberg, Esquire

152 **Ask Sirenhead**
Don't Rain on Their Parade

New Department



Hands On
Gear, Gadgets & Great Ideas

133

Departments

12 **Letters**

18 **EMS News**

25 **Canadian News**

31 **Research Review**

133 **Hands On**

138 **Ad Index**

143 **Classifieds**

154 **Last Word**

2000 **About the cover:** Florida Regional EMS senior paramedic Martin Bundy assesses a three-year-old injured after the church van the child and six others traveled in blew a tire and rolled on the Florida Turnpike. The driver died in the crash, and five other occupants (all unbelted) were ejected and critically injured.

The child pictured, the only restrained vehicle occupant, was found in the vehicle—still strapped in his car seat. Despite the trauma, noise and activity on scene, Bundy offered a reassuring smile to his three-year-old patient and kept the youngster from becoming emotionally upset, which could have altered his vital signs and made it difficult for emergency personnel to accurately assess his condition.

PHOTO CRAIG JACKSON